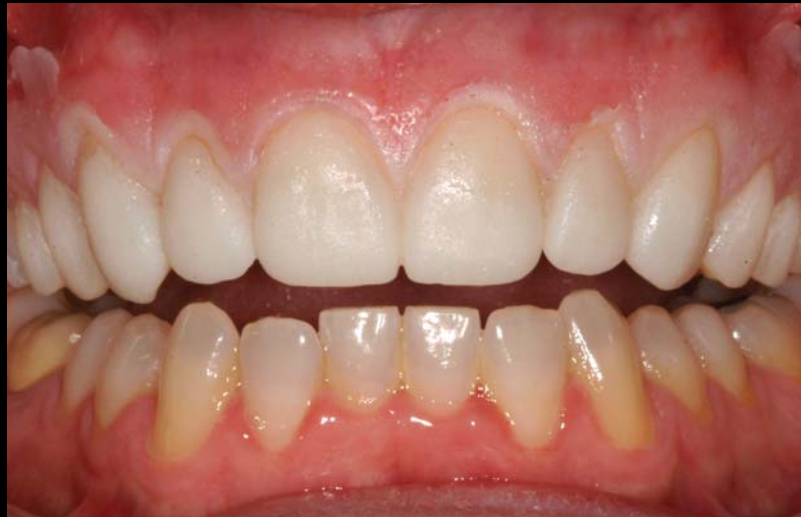

# BEAD LINE VENEER PROVISIONAL RESTORATIONS

Todd Snyder, DDS\*



*Patient expectations for aesthetic restorations, particularly in the anterior region, have extended to the delivery of natural-looking prostheses during the provisionalization period. Contemporary provisionals serve as diagnostic tools, clinical adjuncts, and communication devices to improve the patient's existing condition and ensure development of an optimal restoration. This article discusses the use of the temporization phase to promote improved mastication and speech while delivering a natural-looking interim prosthesis.*

#### Learning Objectives:

This article reviews the use of an efficient provisionalization technique to promote improved function, periodontal health, and aesthetics during the temporization period. Upon completing this article, the reader should:

- Recognize the role of the provisionalization period on overall aesthetics and form.
- Understand the procedures required to ensure aesthetic provisionalization using a working model and over impression.

*Key Words: provisionalization, anterior, aesthetics, over impression, bead line, model*

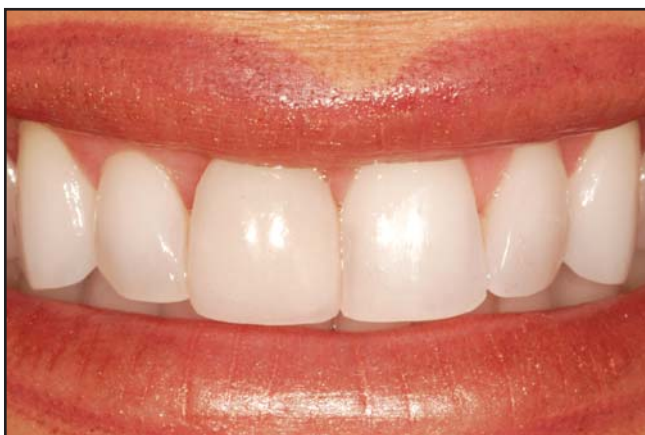---

\*Private Practice, Laguna Niguel, California; private practice, Newport Beach, California.

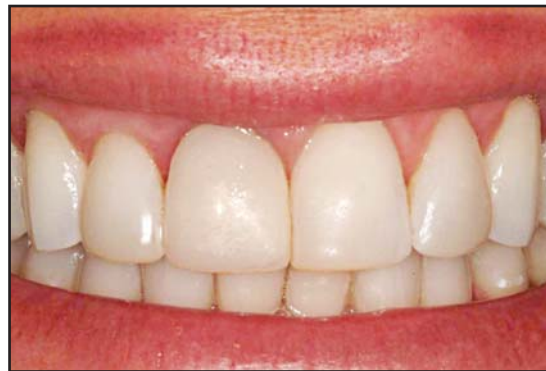Todd Snyder, DDS, 25500 Rancho Niguel Road, Suite 230, Laguna Niguel, CA 92677  
Tel: 949-643-6733 • Email: [tcsnyder@aestheticdentaldesigns.com](mailto:tcsnyder@aestheticdentaldesigns.com) • Website:  
[www.drtdodsnyder.com](http://www.drtdodsnyder.com)

The utilization of provisional restorations in dentistry has numerous functions. Temporaries function as a diagnostic tool to determine occlusion, function, aesthetics, phonetics, tooth position, length, width, occlusal plane, gingival contours, and smile design. Furthermore, they maintain tooth position and prevent occlusal changes during the fabrication process of an indirect restoration. This is crucial for the final restoration to have proper contours, occlusion, and contact to the adjacent and opposing teeth. Additionally, a provisional eliminates sensitivity and allows for the development of gingival contours prior to delivery of the definitive restoration. A provisional should protect the underlying tooth structure from the oral cavity, seal out bacteria and saliva, and thermally protect the tooth.

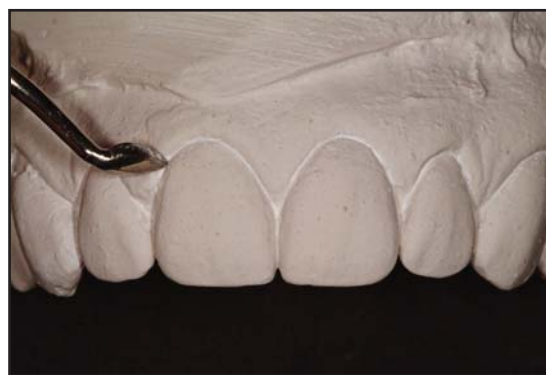Good marginal adaptation, anatomical contour, and a smooth surface are critical for the provisional to facilitate acceptable oral health. This is particularly important when placing subgingival margins so that tissue health remains ideal for cementation. Rough, over- or under-contoured margins can contribute to plaque accumulation and make it difficult for proper oral hygiene. This may lead to compromised gingival health, which can significantly affect the overall health of gingival tissues as well as the aesthetics of the final restoration due to gingival inflammation or gingival recession.<sup>1</sup> The provisional restoration should promote healing of the gingival tissues and the development of proper gingival contours so that the final restoration can be delivered without tissue damage or bone loss.<sup>2</sup> The provisionalization phase also enables maintenance of tooth position; inaccurate



**Figure 1.** Preoperative smile has a buccal corridor deficit, malpositioned lateral incisors, and an existing veneer on #8.



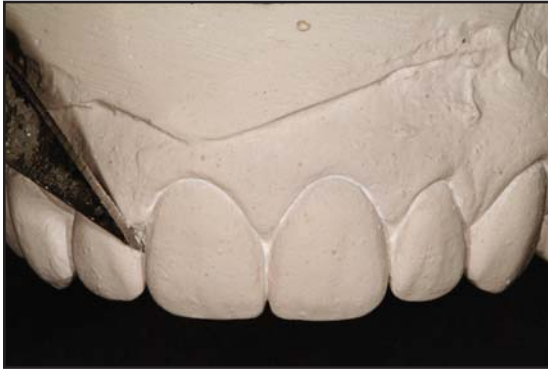**Figure 2.** Following initial tooth preparation, maxillary provisionals were fabricated intraorally with virtually no flash and minimal to no adjustments required.



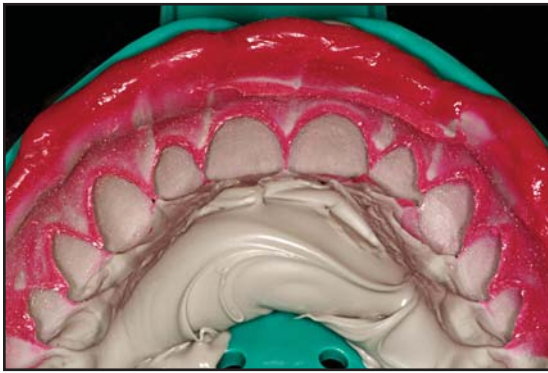
**Figure 3.** Approximately 0.5 mm to 1 mm of tooth structure reduction was needed where the final margin was to be placed.

provisionalization may cause the need for adjustments or potential remakes of the definitive restoration.<sup>3-6</sup>

The utilization of veneer provisionals has progressed over the years due to many advances in techniques and materials. Traditionally, veneers were a very conservative treatment modality that would most often be limited to just the superficial enamel tooth structure and the interproximal contact would be left intact such that no anesthesia or provisionals were indicated. As the veneering process has evolved, the ability to make teeth appear as though they have been repositioned has caused the preparation designs to occasionally become more aggressive, resulting in the exposure of dentin. This had created the need for provisionals so that teeth would be free of sensitivity, staining, and bacterial invasion, while also maintaining tooth position, gingival health, and function until such time that the veneers can be delivered.



**Figure 4.** Approximately 0.5 mm of marginal tissue reduction was also positioned to facilitate development of bead line provisional restorations.



**Figure 5.** A polyvinylsiloxane impression was captured to enable accurate data transfer to the diagnostic waxup and working models.

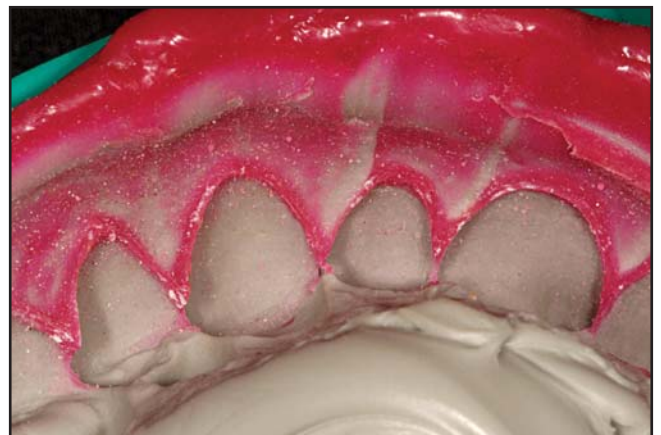One of the earliest forms of provisionalization for veneers was free-hand composite bonding on the exposed tooth structure. This process was slowly replaced with modern bis-acrylic provisionals made from prefabricated clear 0.020 thermoform stents. The excess flash of material made by this technique resulted in a tedious clean up process that could potentially be hazardous to gingival tissues and the cavosurface margins if one did not impart extreme care in the removal process. Stents have been replaced often with putty or polyvinylsiloxane (PVS) matrices made from diagnostic wax-ups of mounted study models. This allows for more accuracy in embrasure spaces and contours, which leaves less material to adjust and remove. Excess material is, however, still extruded out into the gingival embrasures and onto the gingival tissues, which then must be trimmed away meticulously so as not to disturb the gingival margin or the intact gingival tissues.

A modified technique utilizing a PVS matrix was developed where the gingival portion of the matrix was removed from the height of the interproximal papilla gingivally. This allowed for any excess material to be wiped off prior to setting in addition to no cleanup being needed on the gingival tissues. The gingival portion of the preparation remains exposed, however, and needs to be covered with a flowable composite.

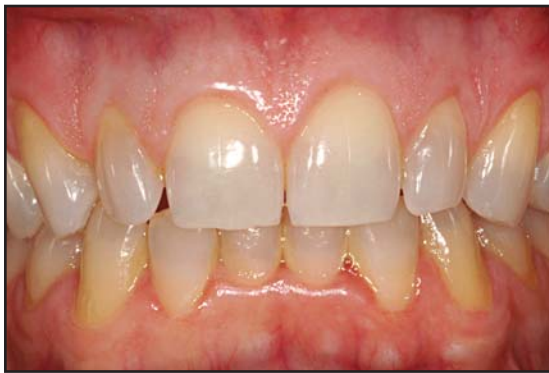The most recent technique called a “Bead Line Provisional” utilizes a PVS matrix contoured in such a fashion that a bead line is cut into the provisional material during fabrication so that any excess is removed effortlessly at the gingival line and interproximally (Figures 1 and 2). This technique can provide immediate results with minimal effort chairside for a beautiful transformation of any smile.

### The Bead Line Provisional Technique

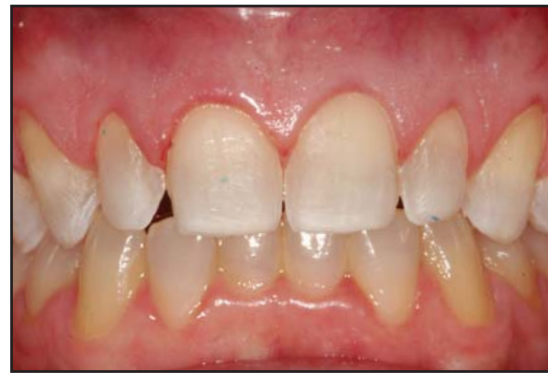The key to fabricating an optimal provisional restoration is in the initial setup, which involves (at minimum) three sets of diagnostic models, showing the teeth and marginal gingival tissues. The models need to be checked for accuracy, a facebow will be needed also to mount the casts properly to an articulator, and the models will then need to be properly articulated and equilibrated.<sup>7</sup> One set of models will stay in the dental office as a control to show original contours and function, as well as to act as an archive depicting the case for legal purposes. The second set of models is used to practice tooth preparation along with proper tooth reduction for the laboratory to then utilize for the



**Figure 6.** The bead lines scribed into the tooth structure on the model function as a pressure point to facilitate separation of the excess material without the need for hand or rotary instruments.



**Figure 7.** Initial appearance prior to tooth preparation for feldspathic veneers on teeth #4(15) through #13(25).

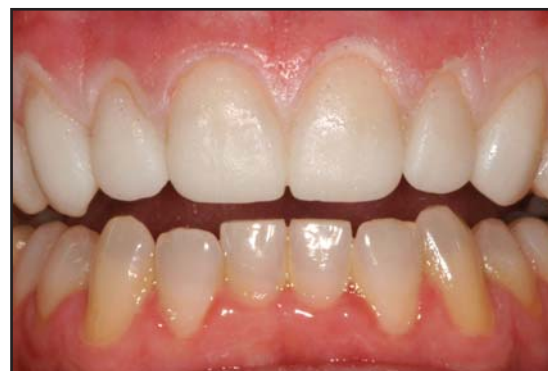

**Figure 8.** A minimally invasive preparation design was selected to allow maintenance of natural tooth structures while addressing the patient's aesthetic concerns.

diagnostic wax-up. The ideal reduction should be performed on each tooth that is to be waxed, with no alteration to the gingiva. This area should remain untouched as it will be instrumental in the fabrication of the provisional. The final tooth-reduction parameters can be delegated to the laboratory. This step does, however, enable the clinician to obtain valuable information with regard to the preparation of malpositioned, rotated teeth that may have unaesthetic diastema spacing and will require careful evaluation of occlusion. Therefore, preparation of the teeth on the model should be performed by the dentist to facilitate this close evaluation. In addition, the laboratory may prepare the teeth differently than the dentist, which could potentially change the outcome of the entire case. The laboratory will use this prepared model for their diagnostic wax-up.

The third model's function is a standby in case a model is damaged or over-prepared. It also acts as a reference of the original position of the teeth for the laboratory to see when fabricating the wax-up. The wax-up is used as the template for the function and aesthetics of the final restorations and gingival tissues. The laboratory needs to be instructed to not wax over the gingival tissues or damage them in any way. Upon completion, the wax-up and models should never have any clear coating applied or sprayed on to them to enhance their appearance as this will change the function of the wax-up and change the true shape of the gingival tissues. A tooth preparation reduction jig can be fabricated from the wax-up for the dentist to utilize to provide the ideal preparation and reduction.

Upon receiving the wax-up, if the patient approves of the final appearance, it can be duplicated by taking

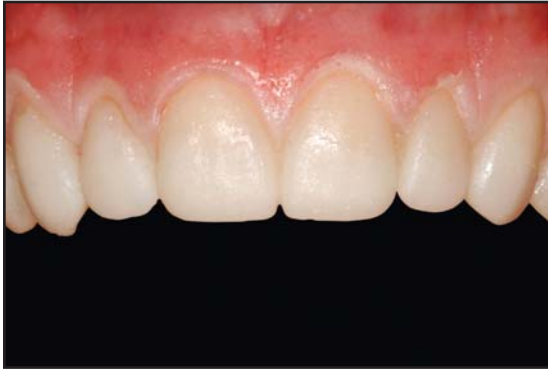

**Figure 9.** Note the immediate function and appearance that do not require any adjustments when the provisional restorations are placed properly.

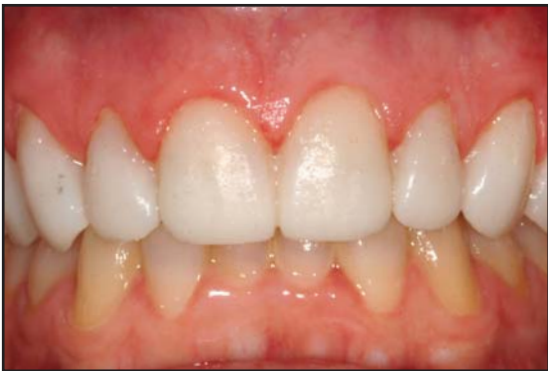an alginate or PVS impression. A model can be fabricated from this impression to start making the bead line provisional. (The laboratory can duplicate the wax-up prior to shipping it back to the dentist; however, if the dentist modifies the wax-up in any way due to patient input, then the duplication of the wax-up made from the laboratory will no longer be accurate.)

### **Modifying the Model**

After pouring the impression of the wax-up with model stone (fast set or standard), any positives on the models should be removed with a scalpel or sharp instrument. Any defects can be filled in with a blockout material. A line is scribed into the root surface of the teeth at the endpoint of the wax-up in the gingival crevice on the now duplicated model. The scribe line should be between 0.5 mm to 1 mm in depth and no wider than 0.5 mm to 1 mm. It should extend around the entire



**Figure 10.** Magnified view of provisional restorations following removal of the bead line template. Note the yellow line from the tooth structure at the gingival margin where the excess acrylic will be peeled off with a hand instrument.

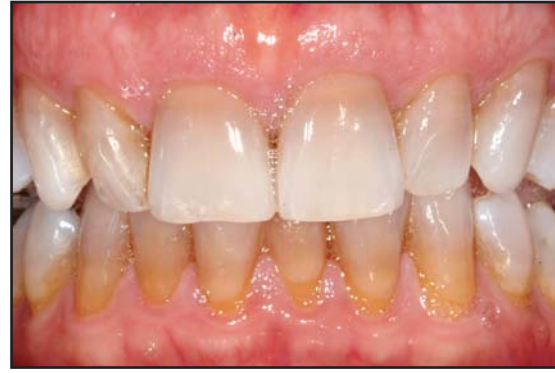

**Figure 11.** Small deficits at the gingival line such as the one apparent on tooth #6(13) were filled in with a flowable composite and the provisional restorations were finalized.

gingival cavosurface margin of the teeth carried into the interproximal so as to allow for flossing of the gingival embrasure spaces (Figure 3).

The ideal placement of the line should be at the most cervical portion of tooth structure without carrying over into the soft tissue. While slight removal of gingival tissue is acceptable, it should ideally be limited to hard tooth structure at this point in fabrication. The next step is to scrape 0.5 mm off of the sulcular gingiva and gingival crest along the marginal gingiva as well as the top and sides of the interproximal papillae (Figure 4). The final step is to take an over impression of the finished model with a PVS wash along with a tray material in a stock tray (preferably a rimlock type tray) (Figure 5).

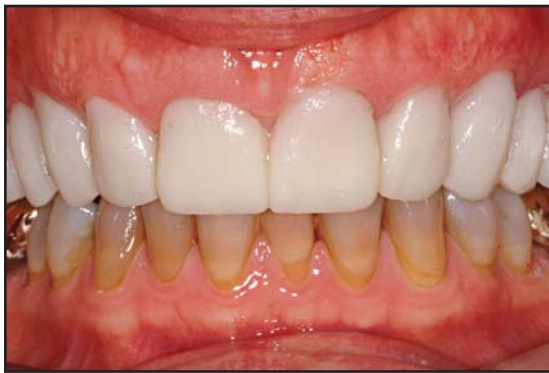How the model is carved will determine how and where the provisional material is cleaved on the preparation day. Interproximal areas on veneers can be carved deep into the stone model but need to be



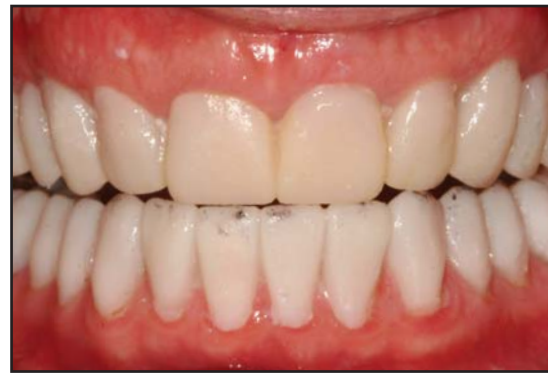**Figure 12.** Preoperative facial appearance showing poor occlusion, malpositioned and discolored teeth.

limited so that they do not completely extend through the interproximal gingival embrasure. Should this happen on a veneer case, wax, composite, or model stone can be placed on the lingual aspect so the impression material will only penetrate thru from the facial aspect when duplicating the model. This will allow for all the provisional material to be contained to the prepared tooth structure and not on the interproximal tissues. If excess blockout material is placed on the lingual aspect, however, the over impression will capture that material and cause a bulk excess of acrylic that would need to be teased out with a scaler or scalpel. Therefore, only a minimum amount of blockout should be added to the lingual gingival embrasure. In the case of a three-quarter veneer or all-ceramic crown, the absence of interproximal tooth structure mandates that the model is handled differently for the interproximal tissues. Unlike the veneer setup where tooth structure would be remaining, the absence of tooth structure for a crown preparation makes the interproximal area more difficult to not have excess provisional material upon fabrication.

When the bead line provisional technique is used for crowns, some interproximal flash may still need to be removed. To avoid having much or any material in this area is again performed on the initial model work prior to the over impression of the bead line model. In this case, a triangular hole at the gingival line is cut interproximally from both the facial and lingual between the teeth; however, they do not touch each other to create a tunnel. This triangular hole can be made in any shape desired to allow for better access to oral hygiene instruments. When an over impression is taken of the model, the impression material will not tear at



**Figure 13.** Following initial tooth preparation, maxillary provisionals were fabricated intraorally with virtually no flash and minimal to no adjustments required.



**Figure 14.** Appearance of the final provisional restorations demonstrates aesthetics, form, and function.

the gingival line due to the two triangular holes not communicating with each other. If the two holes are connected like a tunnel, then impression material can get in there and either lock on the model or tear when it is removed. Upon removal, the bead line over impression for crowns will have a small amount of acrylic that will touch the gingival region. It will be the same thickness as the distance between the two triangular holes cut on the plaster model. To avoid any acrylic in these areas, a small amount of blockout resin, wax, or oral paste can be placed interproximally prior to placing the bead line over impression in the mouth. This slight blockout placed on top of the interproximal papilla will keep the provisional material from closing in the small triangular gingival embrasure.

### **Impression Making Considerations**

When delivering full-arch provisionals, the temporary material may become locked into the over impression if small bumps are placed on a premolar and molar on both sides of the arch during the wax-up. These will be negative areas in the bead line over impression that will allow for the provisional material to solidify in them, causing an undercut that will remove the provisional in the impression. Care must be taken such that the line of draw of all the teeth are the same and that there are no undercuts anywhere that would inhibit the provisional and bead line over impression from being removed. This will facilitate simplified removal of the provisional in the over impression for any final trimming or adjusting that may be necessary. To remove it from the impression, take the entire impression out of the impression tray and then the impression material can be flexed for

easy removal of the provisional. The author recommends rimlock trays for easy removal of the impression material and reseating of the material in the tray, if necessary, to fabricate any additional provisionals.

To create the bead line over impression from the wax-up, a light and a heavy body polyvinylsiloxane material can be used with a rigid tray system. The light body material is syringed on the tooth structure and flowed into the bead line only; care is taken to avoid contacting the gingival tissues. A heavy bodied tray material is then seated with sufficient pressure to ensure precise capture.

The bead lines scribed into the tooth structure on the model function as a pressure point when placed intraorally; this pressure point cleaves the provisional acrylic, allowing for easy separation of the excess material without the need for hand or rotary instruments (Figure 6). The ability of the soft gingival tissues to deform under pressure of the impression material during provisional placement is why they are scraped so that their pressure against the provisional material will minimize any flash in the area, causing it to be extruded away from the preparation.

The bead line stent is filled with acrylic (Fill-IN, Kerr/Sybron, Orange, CA) and then seated firmly to allow for the bead line to fully engage the tooth structure and for the gingival tissues to be compressed. The pressure needs to be maintained until the provisional material has solidified so the compressed gingival tissues and the bead line do not cause the over impression to rebound. Excessive pressure is unnecessary as it may cause distortion; when the bead line provisional stent is seated, it can be depressed firmly with rigid

stops on tooth structure and the hard palate. The soft tissue stops from the bead line at the height of the gingival crest will depress the tissues to cause minimal to no acrylic to be left within 0.5 mm typically of the margin. The bead line margin will leave a perfect line at the margin or possibly slightly shy of the margin, depending on how it was trimmed. In the case of veneers where there is minimal reduction of tooth structure and the reduction is typically limited to the facial surface, a bead line can also be created on the lingual aspect of the tooth anywhere away from the final margin placement or somewhere on the palatal tissue. Should the bead line over impression be overfilled with acrylic, any excess peels away from the teeth and tissues effortlessly as the bead line separates the provisional material that is covering the tooth from the excess that is on the gingival tissues (Figures 7 through 11).

Any slight marginal deficit of the provisional can, however, be quickly and easily corrected with a flowable composite (eg, Premise, Kerr/Sybron, Orange, CA). The composite is flowed into the defect and manipulated, if necessary, with an instrument and then cured. The whole process of seating the provisional should take no more than a few minutes. The final occlusion is checked upon removal of the bead line stent and adjusted, if necessary. Typically, if the wax-up and model mounting were performed properly, minimal to no adjustments will be required. The occlusion can be slightly off if the hard stops for the impression are removed or minimal. If the impression is seated with too much pressure, the provisional material may be thin, under contoured, and out of occlusion. If insufficient pressure was used, the margins may be short, bulky, over-contoured, and high in occlusion. This provisional procedure works well for large full-arch rehabilitations as well (Figures 12 through 14). If incisal color changes are desired, a quick cutback of the incisal edge along with placement of an incisal composite can make for a more polychromatic appearance compared to the single color imparted by the provisional material.

### **Clinical Considerations**

The treatment of tooth structure prior to placement of the provisional material should entail placing an antibacterial agent (eg, Peridex, Zila Pharmaceuticals, Scottsdale, AZ; Consepsis, Ultradent Products, South Jordan, UT) followed by air drying of the material; it is not rinsed away. The material will help inhibit bacterial growth

during provisionalization. The acrylic will harden around the undercuts and line angles on adjacent teeth for veneer provisionals so they do not need to be removed, and cemented in place. The acrylic approximates tooth structure so well that there is very minimal to no visible microleakage. In the case of crown preparations, the line of draw needs to be the same for all the teeth prepared such that the provisional can be removed and cemented in place, if the line of draw is different on adjacent teeth the provisional will not come off. This can remain in place without temporary cement if the stent was fabricated properly with good marginal integrity.

Any adjustment to the provisionals can be performed with 12 or 30 fluted carbides, discs, cups, and brushes (eg, Occlubrushes, Kerr/Sybron, Orange, CA), and surface sealants can also be utilized if desired to provide a highly polished, smooth surface. Superfloss or floss threaders can be utilized interproximally to keep the gingival tissues healthy and free of debris and inflammation due to the accuracy of this provisional technique, allowing for gingival embrasure space.

### **Conclusion**

There are many techniques available to fabricate provisionals for our patients; this is just one of many that can simplify the provisionalization process. The elimination of excess adjustment and flash removal can facilitate a huge time savings, allowing the practitioner to be more productive seeing other patients while also decreasing the risk of tissue or margin damage from trimming excess flash that occurred with earlier provisional stent techniques.

### **Acknowledgment**

*The author declares no financial interest in any of the products cited herein.*

### **References**

1. Waerhaug J. Tissue retractions around artificial crowns. *J Periodontol* 1953;24:172.
2. Nevins M. Interproximal periodontal disease: The embrasure as an etiologic factor. *Int J Periodont Rest Dent* 1982;2:8-27.
3. Mumford JM, Ferguson HW. Temporary restorations and dressings. *Dent Pract Dent Rec* 1959;9:121-124.
4. Segat L. Protection of prepared abutments between appointments in crown and bridge prosthodontics. *J Mich Dent Assoc* 1962;44:32-35.
5. Knight RM. Temporary restorations in restorative dentistry. *J Tenn Dent Assoc* 1967;747:346-349.
6. Rose HP. A simplified technique for temporary crowns. *Dent Dig* 1967;73:449-450.
7. Basta, *Gnathology Guide*, Burlingame, CA.

# CONTINUING EDUCATION (CE) EXERCISE No. 9



To submit your CE Exercise answers, please use the answer sheet found within the CE Editorial Section of this issue and complete as follows: 1) Identify the article; 2) Place an X in the appropriate box for each question of each exercise; 3) Clip answer sheet from the page and mail it to the CE Department at Montage Media Corporation. For further instructions, please refer to the CE Editorial Section.

The 10 multiple-choice questions for this Continuing Education (CE) exercise are based on the article "Bead line veneer provisional restorations," by Todd Snyder, DDS. This article is on Pages E1-E7.

**1. The use of free-hand composite bonding on the exposed tooth structure:**

- a. Is called the bead line provisionalization technique.
- b. Was slowly replaced by modern bis-acrylic provisionals.
- c. Resulted in a tedious clean-up process that often caused damage to the gingival tissues and cavosurface margins.
- d. None of the above.

**2. Excess removal of flash in the gingival region:**

- a. Is undesirable and will assist in overall gingival tissue healing.
- b. Is generally easy to perform and does not ever compromise the gingival tissues.
- c. Can be facilitated by the use of a PVS matrix contoured to allow placement of a bead line cut during fabrication.
- d. None of the above.

**3. Using the bead line provisionalization technique:**

- a. Bead lines are placed at different points across the tooth surface to provide a rigid, striped surface for impression taking.
- b. Any bead lines scribed into the tooth structure function as a pressure point to facilitate separation of any excess impression or modeling material.
- c. Both a and b are correct.
- d. Neither a nor b are correct.

**4. Why is even, sufficient pressure required during placement of the bead line stent?**

- a. Because excessive pressure can cause distortion.
- b. Because insufficient pressure can result in short, bulky, over-contoured provisionals.
- c. Because insufficient pressure can result in inaccurate capture of occlusal data, resulting in poor function.
- d. All of the above.

**5. During the impression-making protocol, it is recommended to use:**

- a. A rigid tray system.
- b. A polyether impression for rigidity.
- c. Both a and b are correct.
- d. Neither a nor b are correct.

**6. It is imperative to remove excess material because:**

- a. The gingival tissues must remain intact.
- b. Excess material may disturb the gingival margin.
- c. Both a and b are correct.
- d. Neither a nor b are correct.

**7. According to the technique described herein:**

- a. The bead line provisionalization technique cannot be applied for full-arch restorations.
- b. Incisal color changes cannot be added because the provisional material is temporary and monochromatic.
- c. Both a and b are correct.
- d. Neither a nor b are correct.

**8. To create the bead line over impression from the wax-up a light body and a heavy body polyvinylsiloxane material can be used with a rigid tray system. The light body material is syringed on the tooth structure and flowed into the bead line only; care is taken to avoid contacting the gingival tissues**

- a. Both statements are true.
- b. Both statements are false.
- c. The first statement is true, the second statement is false.
- d. The first statement is false, the second statement is true.

**9. The author recommends the use of \_\_\_\_ to prevent the provisional material from closing the small triangular gingival embrasure that is placed.**

- a. Wax.
- b. Oral paste.
- c. A small amount of block out resin.
- d. All of the above.

**10. When preparing the model for the bead line provisionalization technique,**

- a. Ideal line placement should be at the most cervical portion of the tooth structure without carrying over into the soft tissue.
- b. Removal of the gingival margin is required to facilitate tissue recontouring.
- c. Approximately 1 mm of sulcular and interproximal gingiva should be removed.
- d. All of the above.